

ID:

2012/11/03

08:29:56

Name:

Mr. Srinivasan P.T.

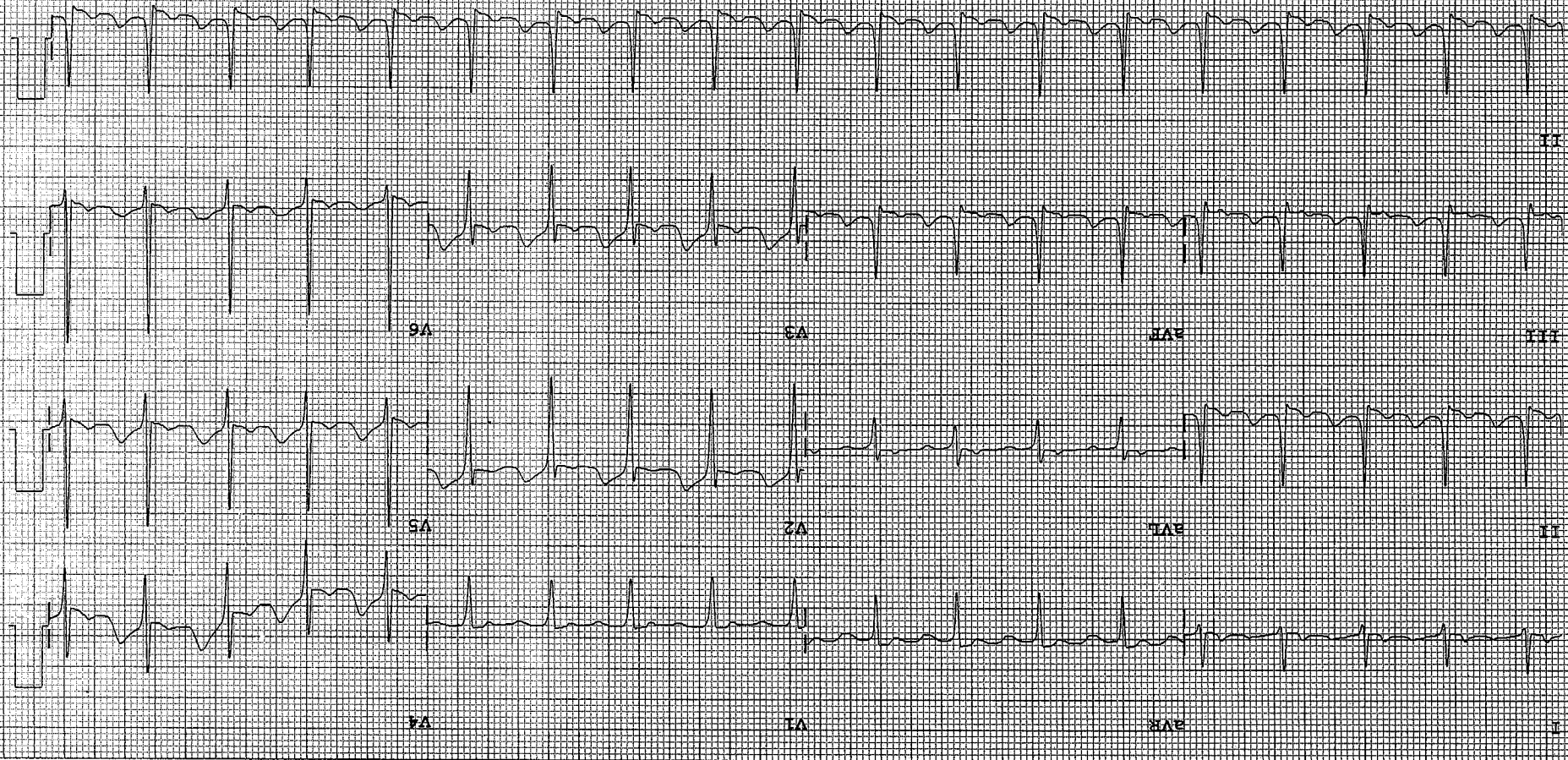
387m

Rate 112
 PR 176
 QRSD 76
 QT 312
 QTc 426
 --AXIS--
 P 36
 QRS 72
 T 68

- OTHERWISE NORMAL ECG -

Unconfirmed Diagnosis

AGE IS NOT ENTERED, ASSUMED TO BE 50 YEARS OLD FOR PURPOSE OF ECG INTERPRETATION
 SINUS TACHYCARDIA.....V-rate> 99
 ST ELEV, PROBABLE EARLY REPOL PATTERN.....ST elevation, age<55



DEV:

Speed 25 mm/sec LIMP: 10 mm/mV Chest: 10 mm/mV

F 50-0.05-40 HZ

PH090A

P2

hearting